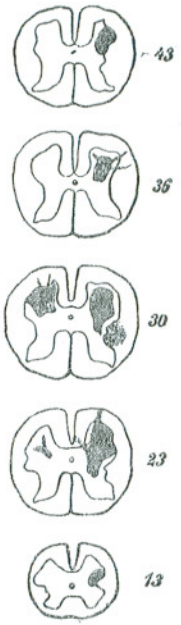

FIG. 1.—Localization of the diseased area in the anterior horns of the lumbar enlargement of the cord in a child two years old, eleven months after the beginning of the disease. A larger area of softening in the right, a smaller one in the left anterior column; 13, 23, 30, 36, and 43 mm. above the termination of the cord. After Roth.

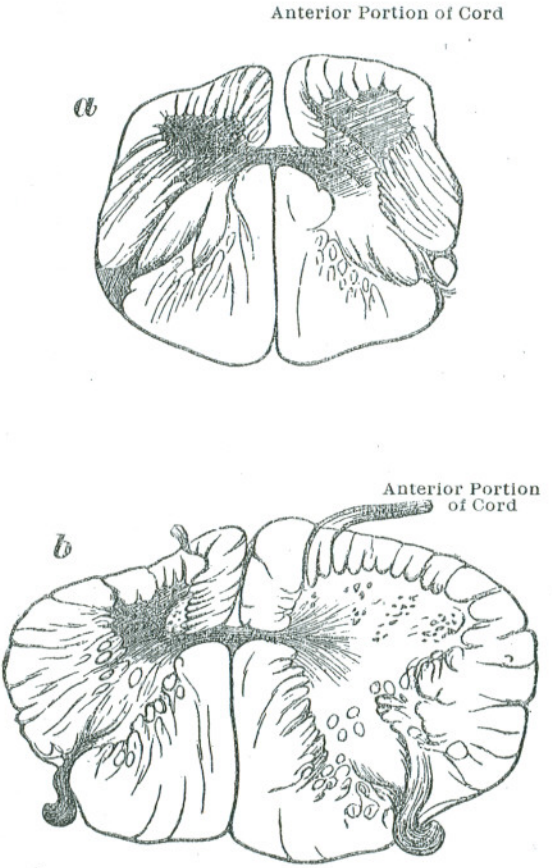

Fig. 2.—Spinal cord with acute spinal paralysis, forty-three years after the beginning of the disease. (a). Section through the lumbar (back) enlargement; both anterior horns and antero-lateral columns strongly shrivelled, more on the left side than on the right. No ganglion-cells are present. (b). Section through the cervical (neck) enlargement; the left anterior horn and antero-lateral column very strongly shrivelled. No ganglion-cells are present. The posterior columns and posterior horns in both sections are normal. A careful study of these figures will reveal much information regarding the lesions in the spinal cord as a result of acute infantile or spinal paralysis. After Charcot and Joffroy.

No. 1.—Cases of Infantile or Spinal Paralysis Reported to the Iowa State Board of Health Office, from January 1, 1910, to August 24, 1910, Inclusive.

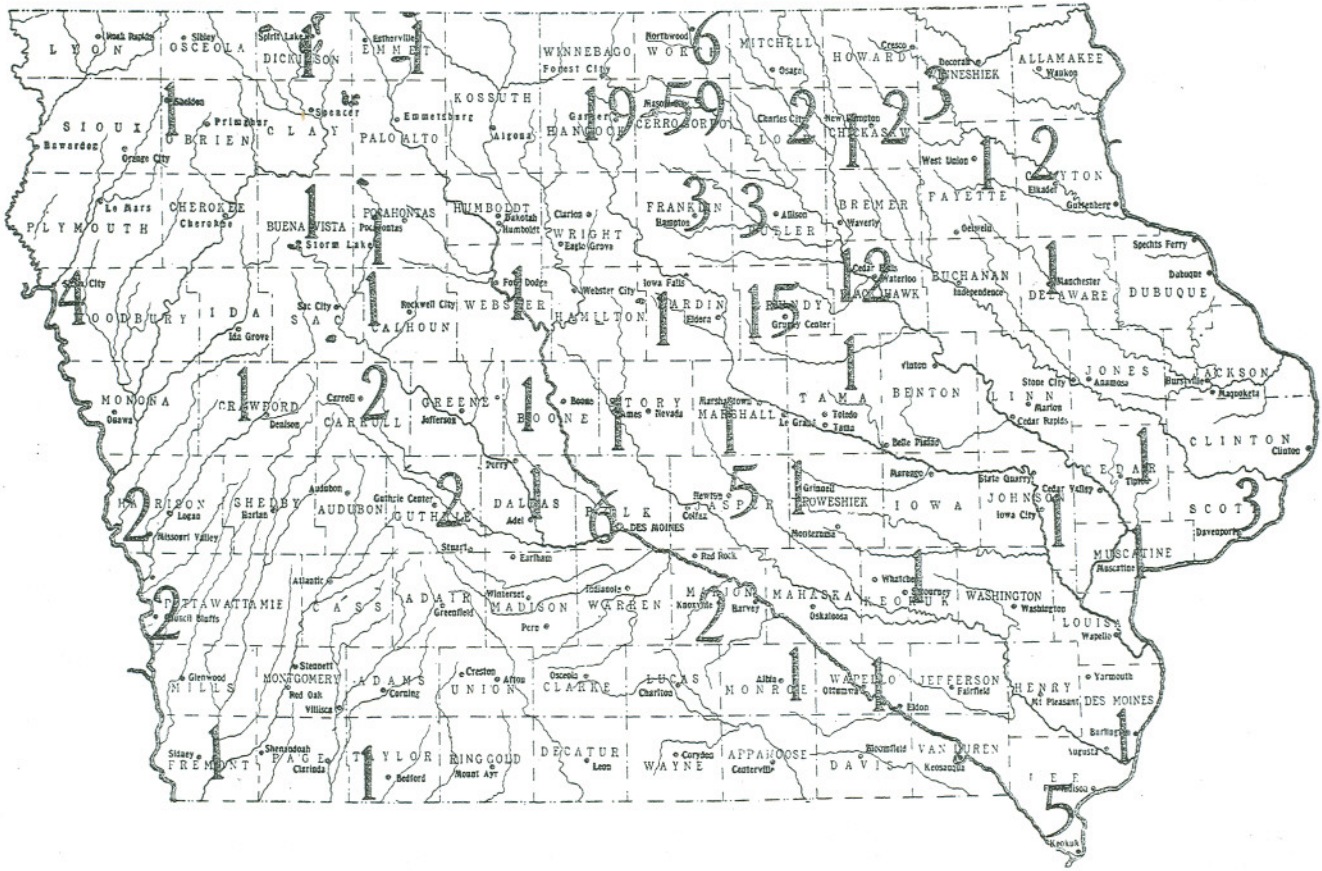

The Dark Figures in each County Indicate the Number of Cases. Total Cases 186.

Map No. 2.—Deaths in Iowa Due to Infantile or Spinal Paralysis, from January 1, 1910, to August 24, 1910, Inclusive.

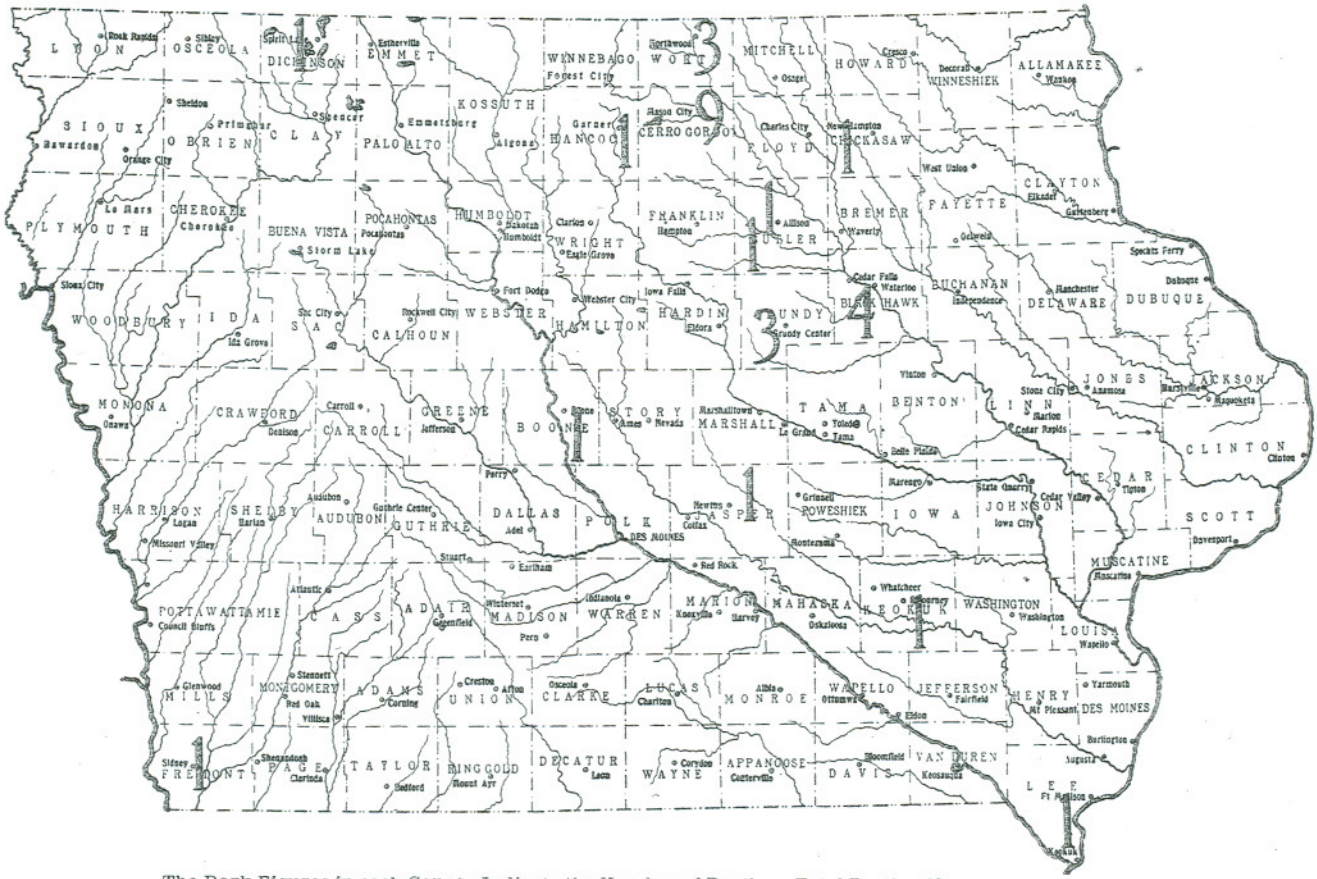

The Dark Figures in each County Indicate the Number of Deaths. Total Deaths. 29.